

About Minimal Hepatic Encephalopathy

Dragos F. VOICU¹,
Lucretia ANGHEL²,
Liliana BAROIU³,
Dorina STAN⁴

¹Faculty of Medicine and Pharmacy, “Dunarea de Jos” University of Galati – Romania; County Emergency Hospital Braila, Romania, dragosfvoicu@yahoo.com

²Faculty of Medicine and Pharmacy, “Dunarea de Jos” University of Galati – Romania.

³Faculty of Medicine and Pharmacy, “Dunarea de Jos” University of Galati – Romania.

⁴Faculty of Medicine and Pharmacy, “Dunarea de Jos” University of Galati – Romania.

Abstract: *Introduction. Hepatic encephalopathy comprises a broad spectrum of neuropsychiatric manifestations, commonly encountered in patients with hepatic dysfunction, in the absence of other concomitant causes of cerebral infarction. Under these conditions, varying degrees of consciousness, neuromuscular dysfunction, cognitive, behavioral and emotional deficits coexist. Minimal hepatic encephalopathy (MHE) is defined by a normal neurological clinical examination but with cognitive deficits that can be highlighted by neuropsychological testing.*

Material and Methods. A retrospective study was conducted on the latest 100 patients (2016-2018), traumatized in road accidents or dropping from their own level, the direct causes of which were apparently inexplicable. The methods included psychometric tests.

Results and Discussion. If 78 patients were known with hepatic cirrhosis and episodically manifested encephalopathy, 20 of them were in treatment for major liver dysfunction, but without encephalopathy, and for 2 patients, the revealing element of hepatic suffering was latent encephalopathy, diagnosed after the road accident. The paper discusses the pathogenesis of hepatic encephalopathy, diagnostic difficulties and its practical implications.

Conclusions. The current gold standard for MHE diagnosis is psychometric testing, which should be completed and revised as MHE is a major public health issue, associating with the risk of unprovoked falls and road accidents. MHE detection, sometimes as the first sign of decompensation of an ignored liver disease, but always as a prodrome of clinically manifest encephalopathy, requires specialized treatment and monitoring.

Keywords: *hepatic encephalopathy; psychometric tests.*

How to cite: Voicu, D.F., Anghel, L., Baroiu, L., & Stan, D. (2020). About Minimal Hepatic Encephalopathy. *BRAIN. Broad Research in Artificial Intelligence and Neuroscience*, 11(1), 70-77. <https://doi.org/10.18662/brain/11.1Sup1/30>

Introduction

Hepatic encephalopathy (HE) comprises a wide range of neuropsychiatric manifestations, commonly encountered in patients with hepatic dysfunction, in the absence of other concomitant causes of cerebral infarction (Bamijoko-Okungbaye, 2018). Under these conditions, varying degrees of consciousness, neuromuscular dysfunction, cognitive behavioral and emotional deficits coexist (Scărlătescu et al., 2014).

According to internationally accepted classification, there are three types of hepatic encephalopathy:

A - associated with acute liver failure;

B - associated with porto-systemic bypass without hepatocellular disease;

C - associated with liver cirrhosis: episodic (spontaneous, precipitated and recurrent), permanent (mild, moderate, dependent on treatment) and minimal. The clinics of HE clinic classically corresponds to the 4th grade, according to the West-Haven scale (*Table I*).

Minimal hepatic encephalopathy (MHE) corresponds to 0 grade, on this scale. Also called sub-clinical or latent encephalopathy, MHE assumes normal neurological clinical examination but with cognitive deficits that can be highlighted by neuropsychological testing.

Table I: The West-Haven Scale for clinically manifested hepatic encephalopathy

Degree	Clinical manifestations
1	euphoria/anxiety, minimal alteration of consciousness, low attention, lowering performance
2	lethargy/apathy, minimal disorientation in time and space, inadequate behavior, discrete personality changes
3	severe disorientation, confusion, drowsiness, stupor
4	coma

The diagnostic criteria for MHE are:

- existence of a disease that can cause HE (such as liver cirrhosis);
- neurological clinical examination within normal limits;
- highlighting of a cognitive dysfunction;
- exclusion of concomitant neurological pain (Zhan & Stremmel, 2012).

Material and Methods

A retrospective study was conducted on the latest 100 patients (2016-2018) traumatized in road accidents or dropping from their own level, the direct causes of which were apparently inexplicable. The methods included psychometric tests (*Fig. 1*).

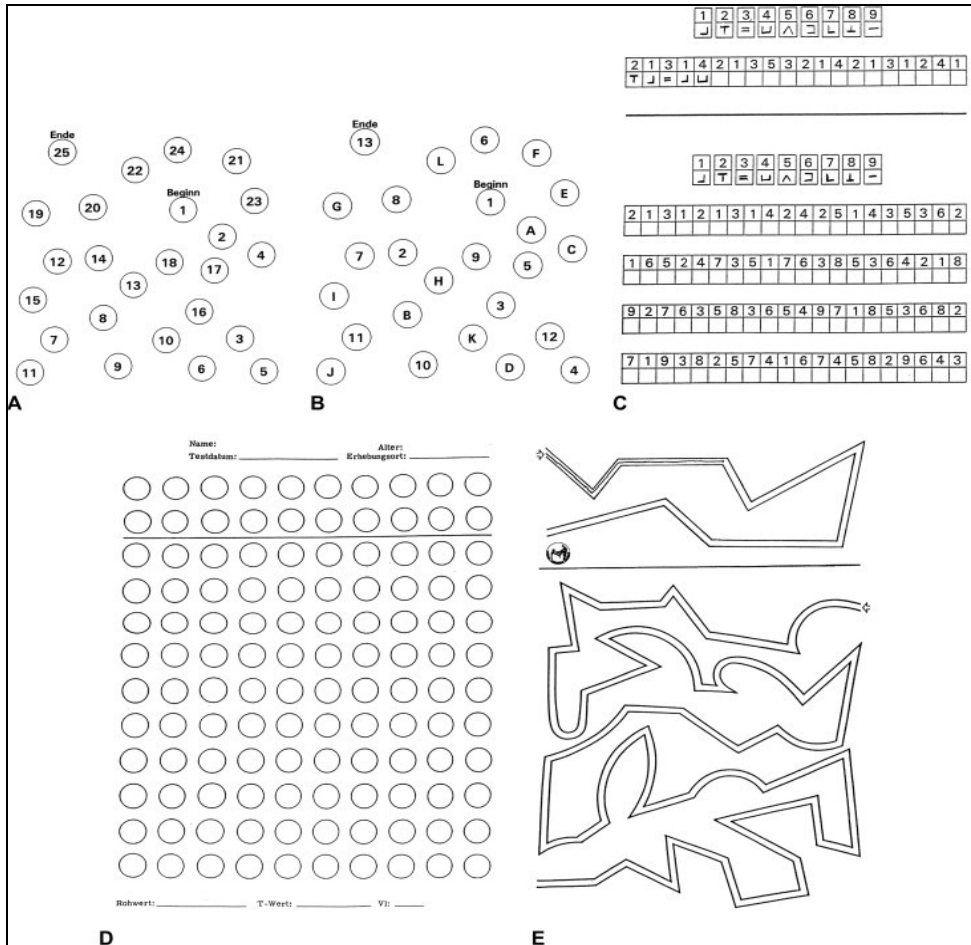


Fig. 1: PSE syndrome test

Legend A-B: connecting consecutive numbers-letters; C: connecting numbers-symbols by model; D: scoring each free circle; E: pencil following route without touching the edges.

For all tests, the time to correct resolution is measured

Results

If 78 patients were known to have liver cirrhosis with episodically manifested encephalopathy, 20 of them were in treatment for important liver dysfunction, but without encephalopathy, and for 2 patients the evidence of liver injury was even latent encephalopathy, diagnosed after the provoked road accident.

Discussions

A careful and tenacious anamnesis, in the context of a clinically apparent neurological assessment, without pathological features, may reveal sleep changes, attention/concentration disorders or memory impairment. Restless sleep, with alterations in circadian rhythm, is quite common in patients with cirrhosis and MHE, compared to those without encephalopathy. However, sleep disturbances cannot be considered pathognomonic for MHE, as they do not necessarily associate with cognitive deficits in cirrhotic patients, but especially with depression. Memory deficiencies also focus on short-term memory and close to nothing, on long-term memory.

Data on the prevalence of minimal hepatic encephalopathy in the literature vary widely (22% -74%) due to the different methods by which it was diagnosed, in the absence of clinical signs. Obviously, MHE prevalence increases with the severity of liver disease, but does not depend on the etiology of liver cirrhosis (excluding recent alcohol consumption). MHE represents in 80% cases the pro-clinical manifestation of HE (Romero-Gómez et al., 2001).

In addition to the well-known and recognized key role of ammonia and its neurotoxicity in HE pathogenesis, the latest research demonstrates the involvement of a much greater number of factors, among which the most important are the persistent systemic inflammation, the intracerebral synthesis of neurosteroids and the hoarding of manganese in the basal nuclei.

- Persistent systemic inflammation (mainly caused by continuous bacterial translocation at the intestinal level) contributes both to the development of MHE and to the development of clinically manifested HE. Serum markers of inflammation have a significantly increased titer in MHE/HE patients, compared to non-encephalopathy patients.

- Neurosteroids (alopregnanolone, tetrahydrodeoxycorticosterone) function as positive modulator receptors for gamma-aminobutyric acid (GABA), thus explaining the increased GABA-ergic tonicity of HE. They

also have intracellular receptors, by which they influence the expression of genes encoding key proteins in astrocytes and neurons. However, the main promoter of neurosteroid synthesis is all hyperammonemia.

- Manganese deposition in the basal nuclei is involved in the pathogenesis of hepatic encephalopathy, but also in the manifest parkinsonism of cirrhotic patients (20% cases).

Experimental reproduction of MHE in the laboratory was performed by progressive ligation of the portal vein. Under these conditions, the following were found in laboratory animals: moderate hyperammonemia, manganese deposition in basal nuclei, circadian rhythm alteration, glutamate accumulation and decreased cortical activation of certain stimuli (Cichoż-Lach & Michalak, 2013; Chen et al., 2012).

MRI spectroscopy confirms the accumulation of glutamine and excess water in the brain, in parallel with the severity of encephalopathy since the incipient stages, which recommends the use of the method in the paraclinical diagnosis of MHE. Also, special MRI techniques revealed structural changes in the thalamic nuclei, caudal nucleus and island lobe in patients with MHE or clinically manifested HE (Scheau et al., 2013; Guevara et al., 2011).

Minimal hepatic encephalopathy affects complex activities involving attention, information processing and psychoemotional abilities (medium or short term planning, car driving), while basic daily activities (hygiene, diet, dressing, etc.) are carried out normally. Other clinical trials have shown significant impairment of emotional behavior, social interactions, work, sleep in cirrhotic patients with MHE, compared with non-encephalopathy cirrhotic patients (Ridola et al., 2018).

Patients with liver cirrhosis and MHE are more likely to suffer road accidents, either due to driving errors (excessive speed, forbidden circulation), overestimation of their own ability to control the car or falling asleep at the wheel. The risk of unprovoked falls from their own level is eight times greater in patients with MHE than in the absence of encephalopathy (Bajaj et al., 2008; Soriano et al., 2012).

Currently, the gold standard in the MHE diagnosis is psychometric tests, with the only mention that they are sometimes difficult to apply in the absence of a consensus on the best combination of tests and the unanimous acceptance of a threshold value for their interpretation (Swaminathan et al., 2017; Weissenborn, 2015). Psychometric testing should be preceded by a neurological examination (including MMSE-Mini Mental State Examination) to exclude dementia. Regarding neurophysiological tests (EEG, computerized EEG, critical flicker frequency) and neuroimaging

(conventional MRI, MRI, PET, SPECT spectroscopy), these are only complementary and are mainly used for research.

The Guide to the International Society for Hepatic Encephalopathy and Nitrogen Metabolism (ISHEN) recommends two sets of neuropsychometric tests: RBANS (Repeatable Battery for the Assessment of Neuropsychological Status) and PSE-Syndrome Test (Figure 1), both meeting the validation criteria used in evaluating patients at risk for MHE (Randolph et al., 2009; Das et al., 2014; Chitescu et al., 2018).

Conclusions

The MHE diagnosis involves the demonstration of a subclinical cognitive dysfunction, performed by psychometric tests, in a patient with liver cirrhosis/portostemic shunt, under normal neurological examination.

MHE is a major public health issue as it is associated with the risk of unprovoked falls and road accidents.

MHE may be the first sign of severe liver injury and predict clinical manifestation of EH.

MHE detection involves initiating standard treatment for hepatic encephalopathy.

References

- Bajaj, J. S., Hafeezullah, M., Hoffman, R. G., Varma, R. R., Franco, J., Binion, D. G., Hammeke, T. A., & Saeian, K. (2008). Navigation skill impairment: Another dimension of the driving difficulties in minimal hepatic encephalopathy. *Hepatology*, *47*(2), 597-604. <https://doi.org/10.1002/hep.22032>
- Bamijoko-Okungbaye, A. (2018). Neuroimaging and the Limits of Brain Imaging Techniques. *Postmodern Openings*, *9*(3), 64-75. <http://dx.doi.org/10.18662/po/36>
- Chen, H. J., Zhu, X. Q., Shu, H., Yang, M., Zhang, Y., Ding, J., Wang, Y., & Teng, G. J. (2012). Structural and functional cerebral impairments in cirrhotic patients with a history of overt hepatic encephalopathy; *European Journal of Radiology*, *81*(10), 2463– 2469. <https://doi.org/10.1016/j.ejrad.2011.10.008>
- Chitescu, C. L., Radu, A. D., Aciu, F., Moraru, M., & Fulga, I. (2018). New psychoactive substances (NPSs) abuse in Romania: Analytical strategies for drug screening in biological samples using high resolution mass spectrometry. *Romanian Journal of Legal Medicine*, *26*(2), 173-182. Retrieved from <http://www.rjlm.ro/system/revista/46/173-182.pdf>
- Cichoż-Lach, H., & Michalak, A. (2013). Current pathogenetic aspects of hepatic encephalopathy and noncirrhotic hyperammonemic encephalopathy. *World*

- Journal of Gastroenterology*, 19(1), 26-34.
<https://doi.org/10.3748/wjg.v19.i1.26>
- Das, S., Ali, S. M. J., Seward, J., & Venkataraman, J. (2014). The mind and liver test: A new approach to the diagnosis of minimal hepatic encephalopathy in resource-poor settings. *International Journal of Hepatology*, 2014, 1-9.
<https://doi.org/10.1155/2014/475021>
- Guevara, M., Baccaro, M. E., Gomez-Anson, B. Frisoni, G., Testa, C., Torre, A., Molinuevo, J. L., Rami, L., Pereira, G., Sotil, E. U., Córdoba, J., Arroyo, V., & Ginès, P. (2011). Cerebral magnetic resonance imaging reveals marked abnormalities of brain tissue density in patients with cirrhosis without overt hepatic encephalopathy. *Journal of Hepatology*, 55(3), 564–573.
<https://doi.org/10.1016/j.jhep.2010.12.008>
- Randolph, C., Hilsabeck, R., Kato, A., Kharbanda, P., Li, Y. Y., Mapelli, D., Ravdin, L. D., Romero-Gomez, M., Stracciari, A., & Weissenborn, K. (2009). Neuropsychological assessment of hepatic encephalopathy: ISHEN practice guidelines. *Liver International*, 29 (5), 629-635.
<https://doi.org/10.1111/j.1478-3231.2009.02009.x>
- Ridola, L., Nardelli S., Gioia S., & Riggio, O. (2018). Quality of life in patients with minimal hepatic encephalopathy. *World Journal of Gastroenterology*, 24(48), 5446-5453. <https://doi.org/10.3748/wjg.v24.i48.5446>
- Romero-Gómez, M., Boza, F., García-Valdecasas, M. S., García, E., & Aguilar-Reina, J. (2001). Subclinical hepatic encephalopathy predicts the development of overt hepatic encephalopathy. *American Journal of Gastroenterology*, 96(9), 2718–2723. <https://doi.org/10.1111/j.1572-0241.2001.04130.x>
- Scărlătescu, F., Scărlătescu, E., & Isacoff, D. (2014). Encefalopatia hepatica minima. *Medicina Interna*, 3. Retrieved from <http://www.medicina-interna.ro/articol.php?articol=873&lang=ro>
- Scheau, C., Badarau, A. I., Ghergus, A. E., Popa, G. A., & Lupescu, I. G. (2013). Minimal hepatic encephalopathy diagnosis by resonance spectroscopy. A case report. *Journal of Gastrointestinal and Liver Diseases*, 22 (4), 455-459. Retrieved from <http://www.jgld.ro/2013/4/16.html>
- Soriano, G., Roman, E., Cordoba, J., Torrens, M., Poca, M., Torras, X., Villanueva, C., Gich, I. J., Vargas, V., & Guarner, C. (2012). Cognitive dysfunction in cirrhosis is associated with falls: A prospective study. *Hepatology*, 55 (6), 1922-1930. <https://doi.org/10.1002/hep.25554>
- Swaminathan, M., Ellul, M. A., & Cross, T. (2017). Hepatic encephalopathy: Current challenges and future prospects. *Hepatic Medicine: Evidence and Research*, 10(3), 1-11. <https://doi.org/10.2147/hmer.s118964>

Weissenborn, K. (2015). Diagnosis of minimal hepatic encephalopathy. *Journal of Clinical and Experimental Hepatology*, 5(suppl.1), S54–S59.

<https://doi.org/10.1016/j.jceh.2014.06.005>

Zhan, T., & Stremmel, W. (2012). The diagnosis and treatment of minimal hepatic encephalopathy. *Deutsches Ärzteblatt Online*, 109(10), 180–187.

<https://doi.org/10.3238/arztebl.2012.0180>