

# Functional Implications of Oral Papillomatosis

Elena-Cristina ANDREI<sup>1</sup>,  
Oprea-Valentin BUSU<sup>2</sup>,  
Valentina Gabriela BOBILCA<sup>3</sup>,  
Irina PAUN<sup>4</sup>

<sup>1</sup> PhD student, University of Medicine and Pharmacy Craiova, Craiova, Romania, [andreicristina2201@gmail.com](mailto:andreicristina2201@gmail.com)

<sup>2</sup> Senior Lecturer PhD, Teacher Training Department, University of Craiova, Craiova, Romania, [valentin\\_busu@yahoo.com](mailto:valentin_busu@yahoo.com)

<sup>3</sup> Student, University of Medicine and Pharmacy Carol Davila Bucharest, Bucharest, Romania, [valentina.bobilca@gmail.com](mailto:valentina.bobilca@gmail.com)

<sup>4</sup> Student, University of Medicine and Pharmacy Carol Davila Bucharest, Bucharest, Romania, [irinapaun10@gmail.com](mailto:irinapaun10@gmail.com)

**Abstract:** *The papillomatous lesion has a number of implications that destabilize the normal functioning of the stomatognathic system, but also it has psychological implications. A patient with a papilloma located in an area of maximum visibility tends to be less exposed in public, to reduce socialization, to feel embarrassed. Oral papilloma affects the masticatory function, phonation, but also aesthetics.*

*Understanding how local immunity works in patients diagnosed with oral papilloma is essential. Local immunity influences the evolution of the papillomatous oral lesion. Toll-like receptors are extremely important in the immune process of oral papilloma. Toll-like receptors can be used as indicators of lesion progression. A reduced expression of these receptors in the focus of the lesion is suggestive of pathological progress. It is also emphasized that in the oral cavity we find a well-represented local immune system which cells have an immune role and whose expression influences the evolution of the disease. The most incriminating factor in the occurrence of oral papilloma is HPV infection. The persistent inflammatory process produced by the HPV virus stimulates the development of oral, pharyngeal, laryngeal neoplasms. The HPV virus acts as a direct inducer in the process of transforming the benign lesion into a malignant lesion. Macrophages play an important role in the malignancy potential induced by the HPV virus. Macrophages are activated by increasing the metabolic rate and fighting tumor cells.*

**Keywords:** *oral papilloma; local immunity; HPV; Toll-Like receptors; psychological implications.*

**How to cite:** Andrei, E.-C., Busu, O.-V., Bobilca, V.G., & Paun, I. (2022). Functional Implications of Oral Papillomatosis. *BRAIN. Broad Research in Artificial Intelligence and Neuroscience*, 13(2), 51-58. <https://doi.org/10.18662/brain/13.2/331>

## **Introduction**

### ***Etiology***

The oral papilloma is a lesion of the squamous epithelium of the mouth frequently associated with the presence of HPV infection at this level (Orenuga, Oluwo, Oluwakuyide, & Olawuyi, 2018). In addition to that, the presence of HPV in asymptomatic patients has been proven to be approximately 7% for all HPV genotypes (Tam, et al., 2018). It is of great importance that this lesion is accurately diagnosed and treated accordingly.

Human papillomavirus is a pathogen with up to 200 different genotypes, that can be further categorised as being low-risk variants such as 6, 11 or 32 and high-risk variants, 16 and 18 (Testi, et al., 2016). In the oral cavity, an infection with the former can commonly cause condilomas. The latter have been known to cause malignant transformations of the squamous epithelial tissue that can lead to the occurrence of oral cacinomas (Syrjänen, 2018).

### ***Transmission***

Oral papillomas can be acquired in many ways. One of these is represented by horizontal transmission. Traditionally, papillomatosis, regardless of the localisation, is viewed as a sexually-transmitted infection. The sexual component of transmission is not to be neglected, as the number of lifetime sexual partners has been found to be a significant risk factor for head and neck HPV-related cancer<sup>3</sup>, in spite of oral sexual practices not being predictive of infection (D'Souza, et al., 2016). More examples of horizontal transmission are through contact with contaminated objects or skin-to-skin contact with an afflicted person.

Cases of vertical transmission have also been documented, HPV being present in the placenta and amniotic fluid. The most frequent manner is the fetus passing through the mother's infected vaginal canal. The chance of transmission grows with the mother's viral load (Ryndock, & Meyers, 2014). This explain the presence of HPV infection in infants. Although the most frequent genotype found was high-risk HPV16, these oral infections has proven to be transitory in young children (Berretta, et al., 2013).

Another situation worth mentioning is that of the stomatological clinic. Both the dental care provider and the patient can be exposed to infection if certain measures are not applied. Certain plastic instruments can be sources of infection if not properly sterilized, as HPV can last up to one week on surfaces (Petca, et al., 2020). Furthermore, viral particles being

dispersed during ablations or excisions in the oral cavity can predispose medical professionals to HPV infections (Pavan, et al., 2020).

### ***Epidemiology***

Globally, approximately 38 000 cases of head and neck malignancies are attributable to Papillomavirus infection. Three types of such cancers have been associated with this virus: oropharyngeal, laryngeal cancer and cancer of the oral cavity (de Martel, Plummer, Vignat, & Franceschi, 2017). According to GLOBOCAN, in 2020, more than 377 000 cases and 177 000 deaths have been registered around the globe and attributed to the HPV infection. In contrast with endometrial carcinoma, esopharyngeal and oral cavity malignancies mainly affect states with a high human development index. Worth noting is the fact that incidence rates as well as mortality rates are lower for women.

HPV information center estimates that in Europe 58.000 women are diagnosed with cervical from which 26.000 die every year, making it the 9th most frequent tip of cancer among women. Oral cancer has a higher incidence and mortality in men comparing to women in Europe and Romania and in case of both sexes the number of cases and deaths grows with the age.

### ***Types of oral papilloma***

Benign lesion associated with HPV are the following: squamous papilloma, verruca vulgaris, condyloma acuminatum and multifocal epithelial hyperplasia or Heck's disease, all most commonly attributed to the low-risk genotypes of the virus (Betz, 2019). Squamous papilloma is the main oral lesion, being recognised by its "cauliflower-like" surface. Verruca vulgaris, a sessile, exophytic lesion, the most common cutaneous manifestation of infection, is not as common in the oral region. Condyloma acuminatum is usually found in the genital area, oral infection leading to a suspicion of sexually-acquired infection (Pringle, 2014). Squamous cell carcinoma of the head and neck is a group of neoplasms originated in the mucosal surface of the oral cavity that is associated with the HPV infection, the 16th variant being the most prevalent type in 90% of the cases (Hübbers, & Akgül, 2015).

### **Case Report**

A 40-year-old male patient presented to the Oro-Maxillo-Facial Surgery Clinic of the Craiova Emergency Hospital for a localized lesion in the lingual organ. The patient does not have any systemic disease and does

not follow any drug treatment. As vicious habits we note smoking (about 15 cigarettes per day) and drinking coffee. The beginning of sexual life was at the age of 16 and the patient is currently married. Following the anamnesis performed, it is noted that the lesion had a slow growth, the beginning of its appearance being a year and a half ago. The initial size of the lesion was imperceptible in the early stages and did not alter the normal functions of the stomatognathic system. As the lesion grew in size, the patient began to feel discomfort during chewing food, burning sensations, and irritation from contact with hot or spicy foods or drinks. When the lesion reached important dimensions (0.8 centimeters), the patient also complained of phonation and aesthetic disorders. The lingual papilloma is located at the apical level of the lingual organ, which makes the lesion visible during speech. The patient also noticed the occurrence of lesional bleeding in cases of accidental contact with rough food or toothbrush. Following discussions with the patient, he stated that he did not know if any family members had been diagnosed with Human Papilloma Virus infection in the past or present.

Clinical aspect: the lesion has an oval shape, regular contour, pink-reddish color, dimensions of 0.8 centimeters, wide implant base.

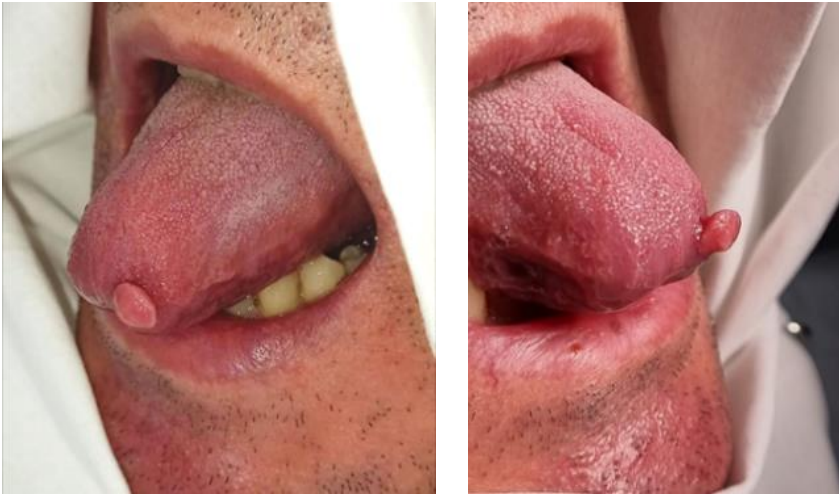With the patient's consent, the surgical excision of the lingual papilloma was performed by the classic scalpel technique. Local anesthesia was performed by infiltration with anesthetic substance with adrenaline for optimal vasoconstriction that reduces bleeding. Throughout the operation, the patient was cooperative and calm.

For histological examination, the lingual mucosal biopsy was fixed in 10% formalin for 24 hours, embedded in paraffin, sectioned at 4 microns and the general histological staining was performed: hematoxylin-eosin and trichromic according to the standard protocol.

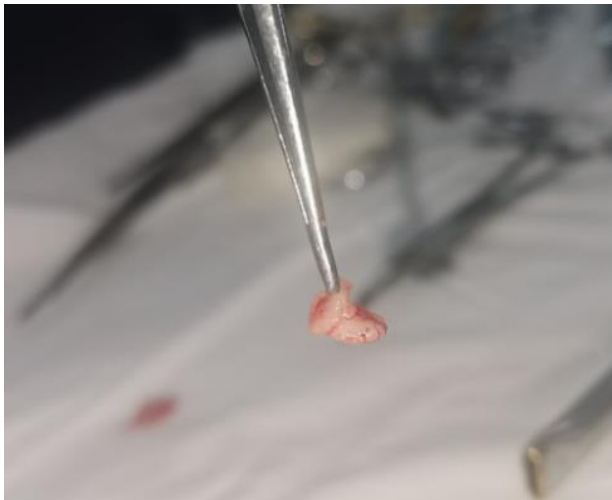
The histological examination revealed the following aspects:

- hyperkeratosis;
- acanthosis;
- presence of koilocyte cells in the spinous layer.

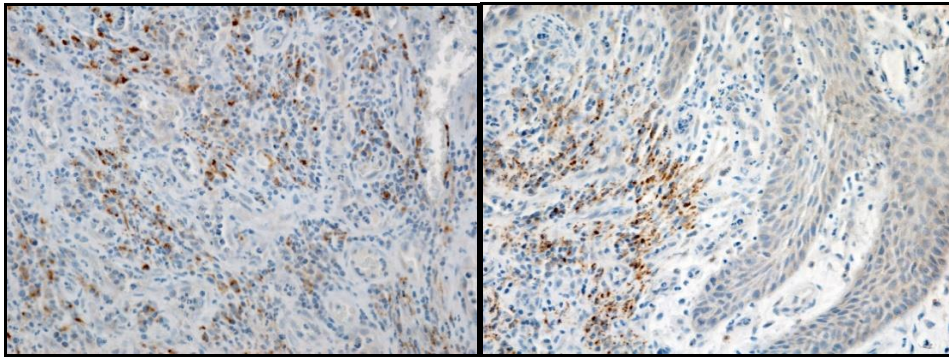
We also performed immunohistochemical reactions in which we used monoclonal anti-HPV antibodies: Anti-HPV antibody [KIH8] (ab245950) which reacts with all types of HPV viruses.



**Fig. 1** Oral papilloma located on the dorsum of the lingual organ at the apex



**Fig 2.** Fragment of the lingual mucosa excised by classic surgical procedure



**Fig. 3.** Lingual mucosa biopsy. Immunohistochemistry antibody anti-HPV[K1H8] (ab245950) positive reaction

## Discussions

- Oral papillomatous lesions tend to affect an increasing number of subjects (Tam, et al., 2018);

- We note that most patients avoid presenting in the early stages and reach specialist control when the injury affects the quality of life. In the present case, the patient complained of mastication, phonation and aesthetic disorders.

- postponing the visit to the doctor can endanger the patient's life if the lesion is infected with HPV viruses, especially oncogenic strains type 16 and 18 (Syrjänen, 2018);

- according to recent studies, the patient is in the risk group for infection with HPV virus because he is a smoker (Zang, & Hu, 2021);

- lack of information on vaccination prevention methods (Gilkey, & McRee, 2016);

- the correct information of the family members regarding the presence of the infection and the mode of transmission (Petca, et al., 2020; Kero, & Rautava, 2019);

- the importance of performing the histological and immunohistochemical examination to establish a certainty diagnosis, but also performing tests that include the study technique of molecular DNA (Alsharif, et al., 2021).

## Conclusions

Oral papillomatous lesions require complex clinical and paraclinical examination before a definitive diagnosis can be made. Correct information to patients about the risks of HPV infection, but also about methods to prevent infection are essential elements in current dental practice.

---

## References

---

- Alsharif, U., Hofmann, M., Gebhard, M., Tharun, L., Rades, D., Sieg, P., & Hakim, S. G. (2021). Double Positivity for HPV DNA/P16<sup>INK4a</sup> Does Not Influence Survival of Patients With Oral Squamous Cell Carcinoma. *Anticancer research*, *41*(11), 5557–5568. <https://doi.org/10.21873/anticanres.15369>.
- Berretta, R., Gizzo, S., Dall'Asta, A., Mazzone, E., Monica, M., Franchi, L., Peri, F., Patrelli, T. S., & Bacchi Modena, A. (2013). Risk of preterm delivery associated with prior treatment of cervical precancerous lesion according to the depth of the cone. *Disease markers*, *35*(6), 721–726. <https://doi.org/10.1155/2013/686027>
- Betz, S. J. (2019). HPV-Related Papillary Lesions of the Oral Mucosa: A Review. *Head and neck pathology*, *13*(1), 80–90. <https://doi.org/10.1007/s12105-019-01003-7>
- de Martel, C., Plummer, M., Vignat, J., & Franceschi, S. (2017). Worldwide burden of cancer attributable to HPV by site, country and HPV type. *International journal of cancer*, *141*(4), 664–670. <https://doi.org/10.1002/ijc.30716>
- D'Souza, G., Wentz, A., Kluz, N., Zhang, Y., Sugar, E., Youngfellow, R. M., Guo, Y., Xiao, W., & Gillison, M. L. (2016). Sex Differences in Risk Factors and Natural History of Oral Human Papillomavirus Infection. *The Journal of infectious diseases*, *213*(12), 1893–1896. <https://doi.org/10.1093/infdis/jiw063>
- Gilkey, M. B., & McRee, A. L. (2016). Provider communication about HPV vaccination: A systematic review. *Human vaccines & immunotherapeutics*, *12*(6), 1454–1468. <https://doi.org/10.1080/21645515.2015.1129090>
- Hübbers, C. U., & Akgül, B. (2015). HPV and cancer of the oral cavity. *Virulence*, *6*(3), 244–248. <https://doi.org/10.1080/21505594.2014.999570>
- Kero, K., & Rautava, J. (2019). HPV Infections in Heterosexual Couples: Mechanisms and Covariates of Virus Transmission. *Acta cytologica*, *63*(2), 143–147. <https://doi.org/10.1159/000494710>
- Orenuga, O.O., Oluwo, A., Oluwakuyide, R.T., Olawuyi, A.B. (2018). Recurrent oral squamous papilloma in a pediatric patient: Case report and review of the literature. *Nigerian Journal of Clinical Practice*, *21*(12), 1674–7. [https://doi.org/10.4103/njcp.njcp\\_407\\_17](https://doi.org/10.4103/njcp.njcp_407_17)
- Pavan, N., Crestani, A., Abrate, A., De Nunzio, C., Esperto, F., Giannarini, G., Galfano, A., Gregori, A., Liguori, G., Bartoletti, R., Porphiglia, F., Simonato, A., Trombetta, C., Tubaro, A., Ficarra, V., Novara, G., & Research Urology Network (RUN) (2020). Risk of Virus Contamination Through

- Surgical Smoke During Minimally Invasive Surgery: A Systematic Review of the Literature on a Neglected Issue Revived in the COVID-19 Pandemic Era. *European urology focus*, 6(5), 1058–1069.  
<https://doi.org/10.1016/j.euf.2020.05.021>
- Petca, A., Borislavski, A., Zvanca, M. E., Petca, R. C., Sandru, F., & Dumitrascu, M. C. (2020). Non-sexual HPV transmission and role of vaccination for a better future (Review). *Experimental and therapeutic medicine*, 20(6), 186.  
<https://doi.org/10.3892/etm.2020.9316>
- Petca, A., Borislavski, A., Zvanca, M. E., Petca, R. C., Sandru, F., & Dumitrascu, M. C. (2020). Non-sexual HPV transmission and role of vaccination for a better future (Review). *Experimental and therapeutic medicine*, 20(6), 186.  
<https://doi.org/10.3892/etm.2020.9316>
- Pringle, G. A. (2014). The role of human papillomavirus in oral disease. *Dental clinics of North America*, 58(2), 385–399.  
<https://doi.org/10.1016/j.cden.2013.12.008>
- Ryndock, E. J., & Meyers, C. (2014). A risk for non-sexual transmission of human papillomavirus?. *Expert review of anti-infective therapy*, 12(10), 1165–1170.  
<https://doi.org/10.1586/14787210.2014.959497>
- Syrjänen, S. (2018). Oral manifestations of human papillomavirus infections. *European journal of oral sciences*, 126 Suppl 1(Suppl Suppl 1), 49–66.  
<https://doi.org/10.1111/eos.12538>
- Tam, S., Fu, S., Xu, L., Krause, K. J., Lairson, D. R., Miao, H., Sturgis, E. M., & Dahlstrom, K. R. (2018). The epidemiology of oral human papillomavirus infection in healthy populations: A systematic review and meta-analysis. *Oral oncology*, 82, 91–99.  
<https://doi.org/10.1016/j.oraloncology.2018.04.005>
- Testi, D., Nardone, M., Melone, P., Cardelli, P., Ottria, L., & Arcuri, C. (2016). HPV and oral lesions: preventive possibilities, vaccines and early diagnosis of malignant lesions. *ORAL & implantology*, 8(2-3), 45–51.  
<https://doi.org/10.11138/orl/2015.8.2.045>
- Zang, L., & Hu, Y. (2021). Risk factors associated with HPV persistence after conization in high-grade squamous intraepithelial lesion. *Archives of gynecology and obstetrics*, 304(6), 1409–1416. <https://doi.org/10.1007/s00404-021-06217-1>