

Potential Screening, Grading and Follow-Up of Diabetic Retinopathy in Primary Care Using Artificial Intelligence – How Hard Would It Be to Implement? An Ophthalmologist’s Perspective

Alexandra Cristina RUSU ¹
Raluca Ozana CHISTOL ²
Simona Irina DAMIAN ^{3*}
Klara BRÎNZANIUC ⁴
Karin Ursula HORVATH ⁵

¹ Doctoral School of Medicine and Pharmacy, Faculty of Medicine, University of Medicine, Pharmacy, Science, and Technology of Targu Mures, 540142 Targu Mures, Romania; Department of Ophthalmology, Emergency County Hospital Targu Mures, 540136 Targu Mures, Romania

² Faculty of Medicine, “Grigore T. Popa” University of Medicine and Pharmacy, 700115 Iasi, Romania; “Prof. Dr. George I.M. Georgescu” Cardiovascular Diseases Institute, 700503 Iasi, Romania; Institute of Forensic Medicine, 700455 Iasi, Romania

³ Faculty of Medicine, “Grigore T. Popa” University of Medicine and Pharmacy, 700115 Iasi, Romania; Institute of Forensic Medicine, 700455 Iasi, Romania

⁴ Doctoral School of Medicine and Pharmacy, Faculty of Medicine, University of Medicine, Pharmacy, Science, and Technology of Targu Mures, 540142 Targu Mures, Romania

⁵ Doctoral School of Medicine and Pharmacy, Faculty of Medicine, University of Medicine; Faculty of Medicine, University of Medicine, Pharmacy, Science, and Technology of Targu Mures, 540142 Targu Mures, Romania

* Correspondence: Simona Irina Damian
si_damian@yahoo.com

Abstract: *Diabetic retinopathy (DR) is a microvascular disorder caused by the long-term effects of diabetes mellitus and among the primary causes of blindness worldwide. Early detection of DR is the key to its effective treatment and subsequent reduction of associated economic burden, but manual screening is time-consuming and of limited availability. A highly sensitive and specific automatic diagnostic tool would significantly improve screening programs and allow referring for further evaluation and treatment in an ophthalmology clinic only patients with significant lesions or with changes between two successive evaluations. Several deep learning-based automated diagnosis tools have been proposed to aid screening but their implementation with minimal costs is not accessible to physicians with no coding knowledge. We aimed to develop a fundus images classification model with no coding knowledge by using generative artificial intelligence (AI) implemented in Windows 11 operating system under subscription (Copilot Pro), a free image analysis tool (Fiji ImageJ2), and Vertex AI, a machine learning (ML) platform launched by Google in 2021. For this purpose, we selected a total of 2961 labelled cases from the APTOS 2019 database of DR fundus images. Images were batch segmented using a Java ImageJ script generated by Copilot Pro and based on the Contrast Limited Adaptive Histogram Equalization (CLAHE) algorithm. Segmented images were used to train an automated ML classification model to detect DR severity (5 classes – no DR, mild non-proliferative DR, moderate DR, severe DR, proliferative DR). The model achieved an area under the precision-recall curve of 0.889, with a precision rate of 83.8% and a recall rate of 77%. In conclusion, generative AI implemented into Windows operating system together with a free imaging processing tool and Vertex AI allow ophthalmologists with no coding knowledge to benefit from publicly available image databases (thousands of cases) to develop accurate automated diagnostic tools. Such tools have the potential to facilitate screening especially in areas with few specialists.*

Keywords: *diabetic retinopathy; artificial intelligence; machine learning; automated diagnosis.*

How to cite: Rusu, A. C., Chistol, R. O., Damian, S. I., Brînzaniuc, K., & Horvath, K. U. (2024). Potential screening, grading and follow-up of diabetic retinopathy in primary care using artificial intelligence – how hard would it be to implement? An ophthalmologist’s perspective. *BRAIN. Broad Research in Artificial Intelligence and Neuroscience*, 15(2), 280-303. <https://doi.org/10.18662/brain/15.2/576>

Introduction

Diabetic retinopathy (DR) is a microvascular disorder caused by the long-term effects of diabetes mellitus on retinal tissues. It numbers among the primary causes of blindness worldwide, particularly affecting patients from their 2nd and well into their 7th decade of life (Teo et al., 2021).

The prevalence of different types of retinopathies increases with the duration of diabetes and patient's age (it is rare before puberty). Concerning the impact of DR on visual acuity, 3.6% of the patients who were diagnosed with diabetes before age 30 and 1.6% of the patients who were diagnosed after age 30 have visual acuity of 1/10 or worse (Centres for Disease Control and Prevention, 2018). The loss of vision in patients with diabetic retinopathy can arise from several pathologic mechanisms such as: clinically significant macular oedema resulting from capillary leakage or microaneurysmal evolution, progressive ischemic maculopathy, transient diabetic papillopathy in precipitous glycaemic control, and neovascularization associated complications (vitreous haemorrhage, epiretinal membrane formation, tractional retinal detachment, neovascular glaucoma).

Standard Macular Fundus Photography is both an effective and accessible DR screening strategy with a sensitivity of >80% in the detection of any grade of DR, and sensitivity and specificity of 97% and 92% respectively for vision-threatening DR (Goh et al., 2016). Early detection of DR is the key to its effective treatment and subsequent reduction of associated economic burden, but manual screening is time-consuming and of limited availability. A highly sensitive and specific automatic diagnostic tool would significantly improve screening programs and allow referring for further evaluation and treatment in an ophthalmology clinic only the patients with significant lesions or with changes between two successive evaluations. Several deep learning-based automated diagnosis tools have been proposed to aid screening but their implementation with minimal costs is not accessible to physicians with no coding knowledge. We aimed to develop a fundus images classification model with no coding knowledge by using generative artificial intelligence (AI) implemented in Microsoft™ Windows 11 operating system (Copilot Pro), Fiji ImageJ2 free image analysis tool (Schindelin et al., 2012), and Vertex AI, a machine learning (ML) platform launched by Google™ in 2021.

Materials and methods

In 2021, Google™ launched a subscription-based machine learning (ML) platform called Vertex AI integrated within Google Cloud™ that allows

training and deploying machine learning models and AI applications without programming knowledge and by using a graphical user interface (GUI). One of the provided options is AutoML (automated machine learning) and we used it to develop classification model for grading diabetic retinopathy.

For this purpose, we downloaded and used the APTOS 2019 fundus images database (<https://www.kaggle.com/datasets/ariaherrerrot/aptos2019>). This database contains 3662 labelled fundus images collected from patients in rural India and graded by trained ophthalmologists as no DR, mild non-proliferative DR (NPDR), moderate NPDR, severe NPDR, and proliferative DR (PDR) (total of 5 classes) according to the International Clinical Diabetic Retinopathy Disease Severity Scale (ICDRSS). The match between image identification code and diagnosis (ground truth) was provided as separate Excel files.

To facilitate training and detection, all images were subject to segmentation using Contrast Limited Adaptive Histogram Equalization (CLAHE) filter implemented in Fiji ImageJ (Schindelin et al., 2012). To batch process images, we asked Copilot Pro (Microsoft™ Windows 11) to write a Java Macro script for ImageJ. After 3 adjustments performed by Copilot Pro after providing the errors returned by ImageJ following initial tests, it generated the final working script:

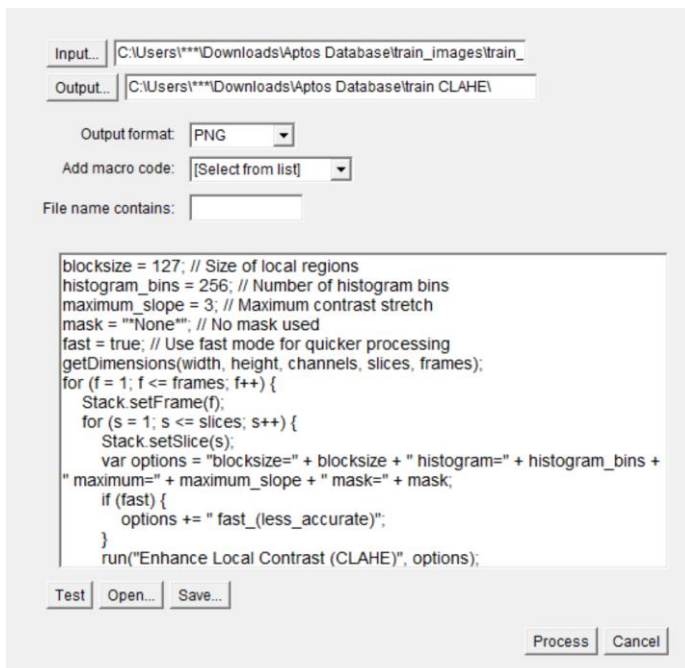


Fig. 1. ImageJ script generated by Copilot Pro

The results of CLAHE segmentation are detailed in image 2.

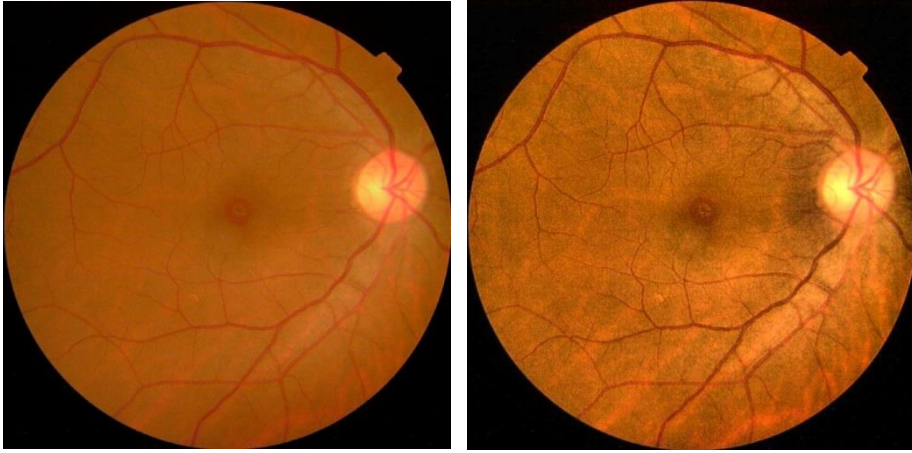


Fig. 2. CLAHE segmentation of fundus images: original image (left) and segmented image (right)

To separate images according to diagnosis encoded in the ground truth Excel file, we asked Copilot Pro to provide a Visual Basic Macro Script for Excel (Microsoft™ 365) that organizes images into subfolders based on the diagnosis specified in the file.

The following correct script was provided together with implementation instructions (fig. 3).

```
3. Write a Script (VBA Macro) in Excel:
o Open your Excel file.
o Press Alt + F11 to open the Visual Basic for Applications (VBA) editor.
o Insert a new module by clicking Insert > Module .
o Copy and paste the following VBA code into the module:

Sub SeparateImagesIntoFolders()
    Dim ws As Worksheet
    Dim lastRow As Long
    Dim i As Long
    Dim idCode As String
    Dim diagnosis As String
    Dim sourcePath As String
    Dim targetPath As String

    ' Set the source folder path (where your images are located)
    sourcePath = "C:\Path\To\Your\Images\"

    ' Set the target folder path (where you want to move the images)
    targetPath = "C:\Path\To\Your\Target\Folders\"

    Set ws = ThisWorkbook.Sheets("Sheet1") ' Change to your sheet name
    lastRow = ws.Cells(ws.Rows.Count, "A").End(xlUp).Row

    For i = 2 To lastRow ' Assuming data starts from row 2
        idCode = ws.Cells(i, 1).Value
        diagnosis = ws.Cells(i, 2).Value
        If Len(diagnosis) > 0 Then
            ' Create the target folder if it doesn't exist
            If Len(Dir(targetPath & diagnosis, vbDirectory)) = 0 Then
                MkDir targetPath & diagnosis
            End If
            ' Move the image file
            Name sourcePath & idCode & ".jpg" As targetPath & diagnosis & "\" & idCode & ".jpg"
        End If
    Next i
End Sub
```

Fig. 3. Visual Basic Macro script for separating images according to diagnosis

Finally, a total of 2961 pre-processed images were successfully uploaded in the Datasets section of Google Cloud™ and manually assigned to the 5 classes – No_DR (1371 images), Mild_NPDR (289 images), Moderate_NPDR (849 images), Severe_NPDR (181 images) and PDR (271 images). Increased file size (>5 Mb), low quality (blurred) and non-labelled images were skipped from uploading. AutoML was chosen as model training method on the us-central1 (Iowa) server. Data was randomly assigned, 80% for training, 10% for validation and 10% for testing with Google-managed encryption key. Higher accuracy was selected for training options with a latency of 200 to 300 ms. We opted for the minimum of 8 node hours training (“node hour” – using ore machine for one hour irrespective of the number of cores).

Results

Total training time for our model was of 1h 38 minutes. The model area under the precision-recall tradeoff curve (AUPRC) for estimating severity grading precision was of 0.889 with a precision rate of 83.8% and a recall rate of 77% at 0.5 confidence threshold (fig. 4).

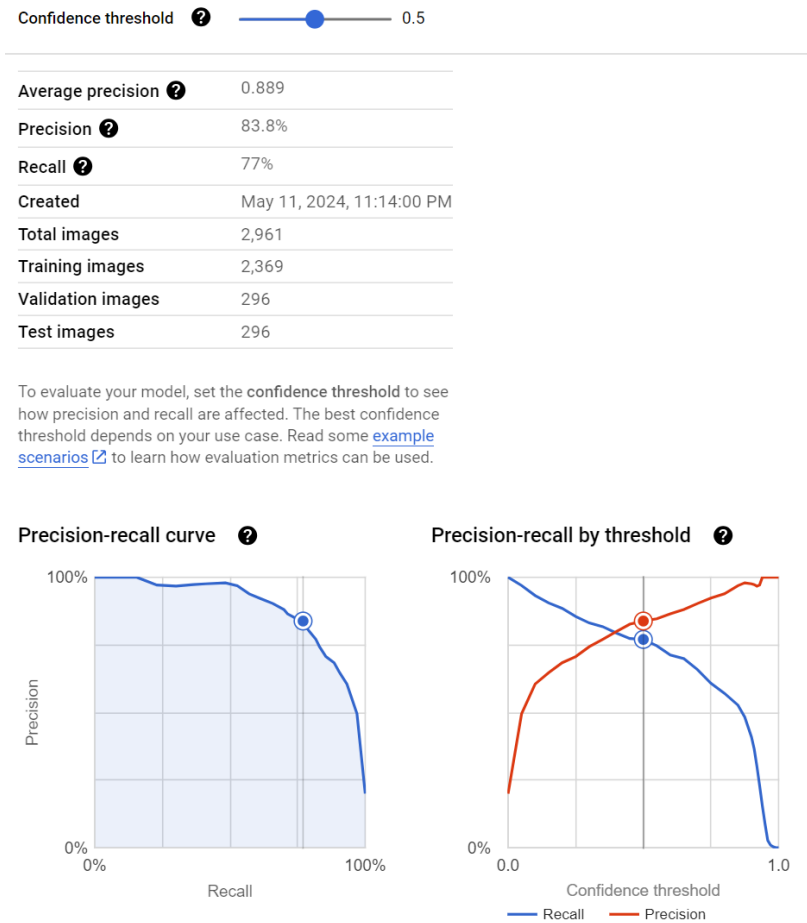


Fig. 4. Precision-recall curve and model features for grading DR

Precision and recall rates varied according to confidence thresholds as shown in table 1. The confusion matrix resulting from the model is detailed in table 2.

Table 1. Precision and recall rates according to confidence thresholds for grading DR

Confidence threshold	Precision rate	Recall rate
0.25	70.7%	85.5%
0.5	83.8%	77%
0.75	92.3%	60.8%

Table 2. Confusion Matrix showing how the model classified each label in the evaluation dataset

		Predicted label				
		No DR	Mild NPDR	Moderate NPDR	Severe NPDR	PDR
True label	No DR	98%	2%	0%	0%	0%
	Mild NPDR	7%	62%	28%	0%	3%
	Moderate NPDR	1%	12%	80%	5%	2%
	Severe NPDR	0%	6%	33%	56%	6%
	PDR	0%	7%	37%	4%	52%

Based on the Confusion Matrix displayed in table 2 we asked Copilot Pro to provide formulas for calculating sensitivity, specificity, positive predictive value, negative predictive value, and accuracy in Excel. We applied provided formulas and obtained the values shown in table 3.

Table 3. Evaluation of the model trained to classify DR

	No DR	Mild NPDR	Moderate NPDR	Severe NPDR	PDR
True positive	1343	179	679	101	141
False positive	28	159	241	53	37
True negative	1563	2513	1872	2725	2653
False negative	27	110	169	82	130
Sensitivity	98%	62%	80%	55%	52%
Specificity	98%	94%	89%	98%	98%
Positive predictive value	98%	53%	74%	66%	79
Negative predictive value	98%	96%	92%	97%	95%
Accuracy	98%	91%	86%	95%	94%

Discussions

The prevalence of vascular affect, translating to different grades of retinopathy, increases with disease duration and patient age (debut rare before puberty). The Wisconsin Epidemiologic Study of Diabetic Retinopathy (WESDR), conducted on a Caucasian population, revealed a

direct relationship between the prevalence of diabetic retinopathy and the duration of diabetes, either type 1 (formerly *insulin-dependent diabetes mellitus*) or type 2 (formerly *non-insulin-dependent diabetes mellitus*) (Klein et al., 2009). After 20 years of diabetes, nearly 99% of type 1 diabetics and 60% of type 2 diabetics exhibit diabetic retinopathy. Moreover, half of the type 1 diabetics and a quarter of the type 2 diabetics develop proliferative diabetic retinopathy after 20 years and 25 years of diabetes, respectively (Klein et al., 2010). Concerning the impact of DR on visual acuity, 3.6% of the patients who were diagnosed with diabetes before age 30 and 1.6% of the patients who were diagnosed after age 30 have visual acuity of 1/10 or worse. According to the National Health and Nutrition Examination Survey (NHANES), vision decline related to diabetes was found in 20.7% of African American diabetics, 17.1% of Caucasian diabetics, and 15.6% of Hispanic diabetics (Hendrick et al., 2015).

While the precise pathophysiologic mechanism involved in the appearance of microangiopathy is still not fully comprehended, the impact of hyperglycaemia and the length of time it persists are recognized as damaging factors, altering the integrity of the vascular endothelium, and causing breakdown of the blood-retina barrier. Diabetes leads to early distinct changes in the retinal capillary network, including the thickening of the basement membrane and pericyte loss; such alterations finally inducing capillary obstruction and retinal ischemia. Moreover, damage of the endothelial barrier equals increased vessel wall permeability, with successive leakage and retinal oedema development (Wang et al., 2018). The ongoing progression of retinal vascular changes gives rise to clinical manifestations corresponding to various disease stages, from early diabetic retinopathy to advanced proliferative diabetic retinopathy. The rate of progression varies among patients and is primarily influenced by systemic factors such as blood glucose levels, blood pressure and lipid profiles.

Hematological and biochemical irregularities are correlated with the prevalence and severity of diabetic retinopathy: increased platelet adhesion, erythrocyte hyperaggregability, increased blood viscosity, lipid metabolism anomalies, fibrinolysis disorders, expression of vascular endothelial growth factor (VEGF), local and systemic inflammation (Wang et al., 2018).

Histologically, diabetic retinopathy is characterized by microangiopathy and vascular changes (focal capillary occlusion, venular dilation, arteriolar hyalinization, capillary basement membrane thickening, pericyte degeneration, microaneurysm formation and haemorrhage) (Garner et al., 1993). Capillary occlusion results in the appearance of focal ischemic areas also known as *cotton wool spots*, intraretinal microvascular abnormalities

(IRMAs - shunts between retinal arterioles and venules near areas of capillary occlusion) and neovascular nascence and proliferation. Microaneurysms are the earliest detectable lesions, initially found temporal to the fovea they may resolve spontaneously. In case of capillary wall rupture, intraretinal dot haemorrhages can be identified. If lesions further progress to the precapillary arterioles of the retinal nerve fibre layer, superficial or flame-shaped haemorrhages may arise as well as soft exudates. Hard exudates (lipid and proteinaceous intraretinal deposits) can be detected later, at the junction of the oedematous and non-oedematous retina. Moreover, vascular damage in diabetes is not limited to capillaries and arterioles, the veins also being affected. This can be quantified by the degree of vessel dilatation, looping or beading. The arterial system also displays peripheral narrowing, silver or copper-wiring, and obliteration. Lastly, as the vascular affect worsens and the rate on nonperfusion increases, neovascularization appears at the disc (NVD) or elsewhere (NVE) in the retina (Jung et al., 2021).

Two scales are currently used for grading diabetic retinopathy, the Early Treatment Diabetic Retinopathy Study (ETDRS, 1991) and the International Clinical Diabetic Retinopathy (ICDR) severity scale (Wilkinson et al., 2003), a simplification of the first. A comparison of the two scales is detailed in table 4 (Yang et al., 2022).

Table 4. Diabetic retinopathy grading scales

ICDR severity levels	ETDRS severity levels	Lesion
No retinopathy	No retinopathy	No lesion
Mild NPDR	Very mild NPDR	Microaneurysms
Moderate NPDR	Mild NPDR	+ retinal haemorrhages and/or hard exudates, and/or cotton wool spots
	Moderate NPDR	+ extensive or severe haemorrhages and microaneurysms or intraretinal microvascular abnormalities
	Moderately severe NPDR	+ venous beading
Severe NPDR	Severe NPDR	Very severe haemorrhages and microaneurysms ± intraretinal microvascular abnormalities or venous beading
PDR	Mild to moderate PDR	new vessels on the disc and/or new vessels elsewhere with or without complications
	Advanced PDR	Retina obscured by vitreous haemorrhage or pre-retinal haemorrhage

Diabetic retinopathy diagnosis presumes both laboratory examinations (fasting blood glucose, glycosylated haemoglobin – HbA1C levels, lipid profile), complete ocular examination (best corrected visual acuity, intraocular pressure, gonioscopy, slit-lamp examination, dilated fundus examination) and medical imaging methods like specific fundus photography protocols (7 standard fields ETDRS montage) or Ultra-Wide Field Imaging (UWFI), fundus fluorescein angiography (FFA), Optical Coherence Tomography (OCT), and if needed further, Ultra-Wide Fluorescein Angiogram (UWFA), ultrasonography, Optical Coherence Tomography Angiography (OCTA).

The most accessible is fundus photography with a sensitivity of >80% in the detection of any grade of DR, and sensitivity and specificity of 97% and 92% respectively for vision-threatening DR (Goh et al., 2016).

Although diabetes control alongside optimization of patient lifestyle and health habits are primordial in retinopathy management, ophthalmologic treatments are designed to improve sight and prevent further vision deterioration. These treatments encompass drug therapies and laser photocoagulation, generally advised for clinically significant central-involved macular oedema. For asymptomatic patients or those retaining normal vision, however, making treatment choices becomes more complex, depending on factors such as degree of glycaemic control, patient compliance to therapy, location of focal oedema in relation to the fovea, the status of the other eye, upcoming cataract or vitreoretinal surgery, the existence of severe PDR, medication history. The American Academy of Ophthalmology advises diabetic maculopathy management prior to undertaking panretinal photocoagulation or cataract procedures to prevent postoperative worsening (Flaxel et al., 2020).

Intravitreal injections of anti-VEGF agents (ranibizumab, bevacizumab, aflibercept) and corticosteroids (triamcinolone acetonide) are routinely used in the management of diabetic macular oedema (DME). Clinical evidence supports their effectiveness and their advantage in improving visual acuity. Intravitreal injections have become routine manoeuvres in ophthalmology, and the possible side effects of this method of administration must be anticipated; these include endophthalmitis, rhegmatogenous retinal detachment, increased intraocular pressure, intraocular haemorrhage, and systemic effects (Ghasemi Falavarjani et al., 2013).

Pars plana vitrectomy along with detachment of the posterior hyaloid can prove a valuable surgical approach for treating advanced diabetic maculopathy. This is particularly relevant when there are indications of posterior hyaloid traction associated with diffuse diabetic maculopathy. Other scenarios where vitrectomy may be beneficial include unresolved intravitreal haemorrhage lasting more than 1 to 6 months, tractional retinal detachment that involves or threatens the macula, mixed tractional and rhegmatogenous retinal detachment, significant recurrent intravitreal haemorrhage despite complete panretinal photocoagulation (PRP), haemolytic glaucoma, ghost cell glaucoma, anterior segment neovascularization with media opacities hindering PRP, and dense premacular retrohyaloid haemorrhage (Gupta et al., 2013).

Screening for diabetic retinopathy

Recognizable retinopathy is uncommon in the first five years after type 1 diabetes is diagnosed, whilst many type 2 diabetes patients already have retinopathy and need ophthalmologic treatment and monitoring at diagnosis. To achieve early-stage diagnosis of diabetic retinopathy and prevent vision loss, the World Health Organization (WHO) recommends annual ophthalmologic examinations for all diabetic patients (Das et al., 2021).

Additionally, because pregnancy can exacerbate diabetic retinopathy, an ophthalmologic exam is advised for all diabetic expecting mothers in the first trimester and then based on the ophthalmologist recommendation. The follow-up visit schedule depends on the severity of retinopathy, history of blood glucose levels, blood pressure, and the potential effect on visual acuity (Das et al., 2021).

Early detection of diabetic retinopathy is key for effective disease management and subsequent reduction of the associated economic burden (Bhuiyan et al., 2021). However, given the progressively increasing number of diabetics worldwide and the relatively small number of ophthalmologists (especially in developing countries and rural regions), a highly sensitive and specific automatic diagnostic tool would significantly improve screening programs, reduce the workload in ophthalmology and thusly, the cost burden. In the past, telemedicine was often employed alongside several algorithms offering low sensitivity rates 66-82% (Teng et al., 2002).

In the era of artificial intelligence, an “ideal” software would automatically detect and adequately grade disease severity with >90% sensitivity and specificity rates while also being capable of tracking changes over time. According to software output, a patient would then be referred for further evaluation and treatment in an ophthalmology clinic.

Certain forms of artificial intelligence, like deep learning that utilises multi-layered neural networks (3 or more layers) to simulate a human brain, are used for image recognition and classification after transforming input data into a more abstract representation. To recognize patterns and classify images, make predictions and decisions, neural networks require training on large sets of images. Detection and classification accuracy increase with the number of training images and number of neural layers in the network.

One of the major limitations to habitual use of deep learning is the tremendous amount of computing power required, with particular emphasis on graphical processing units (GPU) as they are more capable of handling many calculations compared to central processing units (CPU). Thus, images need to be analysed on a computer and not on the acquisition console.

In the following paragraphs we analyse in detail the stages of image analysis with multi-layered neural networks.

- Training databases

Irrespective of the deep learning method used for automatic diagnostic, the algorithm must be trained using pre-classified images. Our research on Google Scholar and PubMed identified a total of 25 databases containing fundus images corresponding to diabetic retinopathy available online for public download (with or without prior registration) or on request download (link sent via email) that could be used separately or mixed into a larger database to train a new network. We briefly present these databases in the order of their inception:

1. *ARIA database (2006)* – 92 fundus images of age-related macular degeneration, 59 fundus images of DR and 61 fundus images of normal cases (ARIA, 2006);

2. *DLARETDB0 and DLARETDB1 Database (2007)* – 130 and 89 fundus images of healthy individuals and graded DR respectively (Kauppi et al., 2007);

3. *EyePACS Database (2009)* – 88702 fundus images of multiple conditions with grading (Cuadros et al., 2009);

4. *ROC database (2010)* – 100 fundus images, 50 training and 50 tests (normal images and microaneurysms) (Niemeijer et al., 2010);

5. *HEI-MED database (2012)* – 169 fundus images corresponding to various degrees of diabetic macular oedema (Giancardo et al., 2012);

6. *Rabbani databases (2012)* – 25 and 35 DR fundus images respectively (Hajeb Mohammad Alipour et al., 2012);

7. *DRiDB database (2013)* – 50 fundus images of graded DR (Prentašić et al., 2013);

8. *E-Ophtha database (2013)* – 463 fundus images corresponding to 47 diabetic patients with exudates, 148 diabetic patients with microaneurysms/small haemorrhages and 268 normal images (Decencièrè et al., 2013);

9. *Diabetic Retinopathy Image Database (DRIMDB) (2014)* – 216 DR fundus images rated as good quality, bad quality and outliers (Şevik et al., 2014);

10. *MESSIDOR and MESSIDOR-2 Database (2014)* – 1748 fundus images of graded DR (Decencièrè et al., 2014);

11. *DR1 and DR2 databases (2014)* – 1077 and 520 fundus images respectively corresponding to DR (hard exudates, superficial haemorrhages, deep haemorrhages, red lesions, cotton-wool spots, drusen) and healthy eyes (Pires et al., 2014);

12. *RetinaCheck database (2015)* – 250 fundus images displaying microaneurysms associated with DR (Abbasi-Sureshjani et al., 2015);

13. *Jichi DR database (2017)* – 2740 fundus images of graded DR (Takahashi et al., 2017);

14. *UoA-DR database (2017)* – 200 fundus images – 56 healthy, 114 non proliferative DR and 30 proliferative DR (Chalakkal et al., 2017);

15. *Hagis database (2017)* – 39 fundus images corresponding to glaucoma, hypertension, DR and age-related macular degeneration (Holm et al., 2017);

16. *IDRiD database (2019)* – 516 fundus images – 413 fundus images of graded DR and 103 test images (Porwal et al., 2018);

17. *ODIR database (2019)* – 5000 fundus images corresponding to 7 conditions and normal aspects (Bodin, 2023);

18. *OLA-DDR database (2019)* – 13673 fundus images of graded DR (Li et al., 2019);

19. *APTOS-2019 database (2020)* – 3662 fundus images of graded DR (Bodapati et al., 2020);

20. *RFMiD Database (2021)* - 3200 fundus images corresponding to 46 conditions (Pachade et al., 2021);

21. *39 Fundus Diseases Database (2021)* - 249620 fundus images from multiethnic data sets corresponding to 39 conditions (Cen et al., 2021);

22. *ROD-rep database (2021)* – repeated 4-field graded fundus images of 70 patients with DR (Retinal Ophthalmology Database Repository, 2021);

23. *FGADR database (2020)* – 2842 fundus images of graded DR (Zhou et al., 2020);

24. *Paraguay Database (2021)* - 757 fundus images of graded DR (Castillo Benítez et al., 2021);

25. *FIVES Database (2021)* - 800 high-resolution multi-disease fundus images (Jin et al., 2021).

Smaller databases (less than 25 images) have been skipped. Similar databases have been developed for other imaging methods (OCT, FFA) and ocular pathologies (for example, glaucoma).

- Image pre-processing

Fundus images are generally RGB images in either .jpeg, .png or .tiff format and of various qualities. Because of intensity variations due to the concavity of the posterior pole, a histogram equalization is necessary. Also, objects of interest must be separated from the rest of the image through segmentation: a process that divides the image into homogeneous zones, according to one or more given attributes such as grey level, texture, or colour, with the aim of separating the various visible components and

identifying them. Furthermore, the purpose of segmentation is to simplify or change the representation of an image into something more meaningful and easier to analyse. There are mainly two approaches to image segmentation: the region-based approach, based on the concept of homogeneity of image areas, and the contour-based approach, which assumes that every area is delimited by closed contours or edges.

Image pre-processing and segmentation can be performed using Python (a high-level, general-purpose programming language), Matlab (a proprietary multi-paradigm programming language and numeric computing environment developed by MathWorks) or Fiji, a free Java image processing package based on ImageJ2 with additional plugins. Even if Python and Matlab seem very complicated for an ophthalmologist to learn and use, researchers worldwide posted their ready to run Python or Matlab code with graphical user interface (GUI) on GitHub (a developer platform that allows developers to create, store, manage and share their code) while describing the segmentation algorithm used. A simple search on <https://github.com> using the keyword “segmentation retina” returned 430 results. When adding “fundus” to the search criteria, results were limited to 25, including 8 Python and 5 Matlab codes. Fiji provides several filters filter for this purpose like Gaussian Blur or Contrast Limited Adaptive Histogram Equalization (CLAHE) which can be incorporated into batch segmentation Macros together with machine learning algorithms such as Weka Segmentation.

- Image analysis using pre-trained convolution neural networks

A Convolutional Neural Network (CNN) is a type of neural network specialized in image processing and classification. A series of pre-trained CNNs for image analysis already exist and they can be used for feature extraction, classification, and transfer learning (table 5) (Das, 2017; Chow et al., 2023). These pre-trained CNN are implemented both in Python (PyTorch) and Matlab (Deep Learning Toolbox Model).

By transfer learning, CNN can be fine-tuned and trained on a new data set, which is both faster and easier than building and training a new neural network from scratch. It is the most popular technique used for pattern recognition and classification of medical images.

Table 5. Pre-trained CNN ordered by depth (number of sequential convolutional or fully connected layers)

Name	Depth	Parameters (millions)	Image Size (pixels)
AlexNet	8	61	227 x 227
VGG-16	16	138	224 x 224
SqueezeNet	18	1.24	227 x 227
ResNet-18	18	11.7	224 x 224
DarkNet-19	19	20.8	256 x 256
VGG-19	19	144	224 x 224
GoogLeNet	22	7	224 x 224
Inception-v3	48	23.9	299 x 299
ShuffleNet	50	1.4	224 x 224
ResNet-50	50	25.6	224 x 224
DarkNet-53	53	41.6	256 x 256
MobileNet-v2	53	3.5	224 x 224
Xception	71	22.9	299 x 299
EfficientNet-b0	82	5.3	224 x 224
ResNet-101	101	44.6	224 x 224
Inception-ResNet-v2	164	55.9	299 x 299
DenseNet-201	201	20	224 x 224

The most popular pre-trained network used for retina fundus images datasets is AlexNet, a CNN with 61 million parameters, 5 convolutional layers and 3 connected layers (total depth of 8 layers). This CNN only accepts 227 x 227 pixels images, so input images would need batch resizing which is also possible in Fiji software (Schindelin et al., 2012). Classification accuracy increases with number of epochs (98% accuracy is indicated with 15 epochs which is time consuming) and batch size (number of input images for one iteration) (Abbas et al., 2023).

Recently, Shamrat et al. proposed a new CNN, namely DRNet13, specifically designed to classify diabetic retinopathy images (no DR, mild DR, moderate DR, severe DR, proliferative DR). This CNN accepts RGB images measuring 224 x 224 pixels and includes 3 sets convolutional layers and pooling layers, a normalization layer, two fully connected layers (dense layers), a dropout layer, and the output layer. This network achieved a 97% accuracy rate for diabetic retinopathy detection with 98% sensitivity and 96% specificity rates (Mehedi Shamrat et al., 2024).

For an ophthalmologist with no coding knowledge and limited computing power creating an image classification system in Matlab or Python is difficult and time consuming.

We attempted to develop an automated DR classification system using digital tools that require no coding, such as generative AI, a free open-source software developed for medical images analysis (Fiji ImageJ2) and an automated ML platform developed by Google™ for general use. For generative AI we opted for Copilot Pro, integrated in Microsoft™ Windows 11 operating system. The Pro version offers faster performance and priority access to Generative Pre-trained Transformer (GPT)-4 and GPT-4 Turbo during peak times and we subscribed for increased functionality. Copilot Pro was used to generate the ImageJ segmentation script, an Excel (Microsoft™ 365) macro script to split the APTOS 19 database into separate folders according to DR severity and Excel formulas for calculating sensitivity, specificity, positive predictive value, negative predictive value, and accuracy rates to assess the classification model.

Copilot Pro can correct the scripts and formulas if errors are adequately reported. In our case, 3 errors reports and corrections were necessary prior to providing a working Java image segmentation script. In case of simple Excel macros and formulas, no errors occurred.

The classification model was developed using automated ML implemented in Vertex AI, a powerful tool that puts the power of machine learning in the hands of non-experts. For image analysis, AutoML offers the necessary tools for training an image classification model that can later be deployed to an endpoint for image upload and prediction.

Our automated model proved comparable to other classification models developed using the same APTOS 19 dataset and various tools requiring computation power and specific knowledge (Table 6).

Table 6. Diabetic retinopathy classification models using APTOS 19 database

	Accuracy	Precision	Method
Shakibania et al., 2023	89.6%	89.23%	CNN ImageNet-pre-trained models, ResNet50 + EfficientNetB0
Oulhadj et al., 2022	93.10%	-	CNN InceptionV3
	91.90%	-	CNN Xception
	90.60%	-	Hybrid DL Approach (VGG16 and VGG19 network models)
Alwakid et al., 2023	98.36%	-	CNN DenseNet-121
Chilukoti et al., 2024	94.2%	94.3%	Transfer learning based on VGG, ResNet, and EfficientNet + ensemble learning
Wong et al., 2023	82.10%	-	Simultaneous Parameter Optimization and Feature-Weighted ECOC Ensemble
Our model	88.9%	83.8%	AutoML Vertex AI

Compared to conventional ML model training that requires an adequate infrastructure (GPUs with ample VRAM) and a strong foundation in statistics, algorithms, big data, and programming languages, AutoML can quickly and accurately select the best model for a given dataset and runs at small costs on virtual machines in Google's massive network and acting as independent computers. Even if AutoML offers limited customization options (both for used hardware and ML), it can be used to develop image diagnosis tools.

What must be also considered, is that while automated diagnosis tools based on AI can become particularly useful in everyday practice, a certain degree of caution must always remain present. To begin with, a full automatization of the diagnosing process would take the control from the human element (the physician and patient). With such an unclear attribution of responsibility, a pertinent legal question arises, in case of misdiagnosis, who should be held liable? The physician using the software tool or software development companies (AI and implementation)? On the other hand, automatic diagnosis tools show increasing rates of specificity and sensitivity in affirming the presence of a certain condition while in pathology grading such rates are significantly lower, as shown by the current study. Compared to human medical doctors, AI is also limited by image quality and patient related variables. While a physician is generally unhindered in making a diagnosis based on low quality images by relying on personal experience, an AI is unable to accurately assess those low quality images based on trained data.

Conclusions

Generative AI implemented into Windows operating system together with a free imaging processing tool and Vertex AI allow ophthalmologists with no coding knowledge to benefit from publicly available image databases (thousands of cases) to develop accurate automated diagnostic tools. Such tools have the potential to equally facilitate screening, diagnosis and therapeutic approach thus enhancing a human ophthalmologists' professional abilities and performance.

References

- Abbas, Q., Albathan, M., Altameem, A., Almakki, R. S., & Hussain, A. (2023). Deep-Ocular: Improved Transfer Learning Architecture Using Self-Attention and Dense Layers for Recognition of Ocular Diseases. *Diagnostics* (Basel, Switzerland), 13(20), 3165. <https://doi.org/10.3390/diagnostics13203165>
- Abbasi-Sureshjani, S., Smit-Ockeloen, I., Zhang, J., & Romeny, B. T. H. (2015). Biologically-inspired supervised vasculature segmentation in SLO retinal fundus images. In *International Conference Image Analysis and Recognition (ICIAR)* (pp. 325–334). Cham.
- Alwakid, G., Gouda, W., Humayun, M., & Jhanjhi, N. Z. (2023). Deep learning-enhanced diabetic retinopathy image classification. *Digital health*, 9, 20552076231194942. <https://doi.org/10.1177/20552076231194942>
- ARIA (2006). Automatic retinal image analysis. <https://paperswithcode.com/dataset/aria/>.
- Bhuiyan, A., Govindaiah, A., Deobhakta, A., Hossain, M., Rosen, R., & Smith, T. (2021). Automated diabetic retinopathy screening for primary care settings using deep learning. *Intelligence-Based Medicine*, 5, 100045. <https://doi.org/10.1016/j.ibmed.2021.100045>
- Bodapati, J. D., Naralasetti, V., Shareef, S. N., Hakak, S., Bilal, M., Maddikunta, P. K. R., & Jo, O. (2020). Blended multi-modal deep ConvNet features for diabetic retinopathy severity prediction. *Electronics*, 9(6), 914. <https://doi.org/10.3390/electronics9060914>
- Bodin, Y. (2023, June 5). Ocular Disease Intelligent Recognition (ODIR-2019). Medium. <https://medium.com/datascientest/ocular-disease-intelligent-recognition-odir-2019-77bb62d42f1b>
- Castillo Benítez, V. E., Castro Matto, I., Mello Román, J. C., Vázquez Noguera, J. L., García-Torres, M., Ayala, J., Pinto-Roa, D. P., Gardel-Sotomayor, P. E., Facon, J., & Grillo, S. A. (2021). Dataset from fundus images for the study of diabetic retinopathy. *Data in brief*, 36, 107068. <https://doi.org/10.1016/j.dib.2021.107068>
- Cen, L. P., Ji, J., Lin, J. W., Ju, S. T., Lin, H. J., Li, T. P., Wang, Y., Yang, J. F., Liu, Y. F., Tan, S., Tan, L., Li, D., Wang, Y., Zheng, D., Xiong, Y., Wu, H., Jiang, J., Wu, Z., Huang, D., Shi, T., ... Zhang, M. (2021). Automatic detection of 39 fundus diseases and conditions in retinal photographs using deep neural networks. *Nature communications*, 12(1), 4828. <https://doi.org/10.1038/s41467-021-25138-w>

- Centers for Disease Control and Prevention (2018). Diabetes Report Card 2017. <https://www.cdc.gov/diabetes/pdfs/library/diabetesreportcard2017-508.pdf>
- Chalakkal, R. J., Abdulla, W. H., & S., S. (2017). Comparative Analysis of University of Auckland Diabetic Retinopathy Database. In 9th International Conference on Signal Processing Systems (pp. 325–334). AUT University, Auckland, New Zealand
- Chilukoti, S. V., Shan, L., Tida, V. S., Maida, A. S., & Hei, X. (2024). A reliable diabetic retinopathy grading via transfer learning and ensemble learning with quadratic weighted kappa metric. *BMC Medical Informatics and Decision Making*, 24, 37. <https://doi.org/10.1186/s12911-024-02446-x>
- Chow, L. S., Tang, G. S., Solihin, M. I., Gowdh, N. M., Ramli, N., & Rahmat, K. (2023). Quantitative and Qualitative Analysis of 18 Deep Convolutional Neural Network (CNN) Models with Transfer Learning to Diagnose COVID-19 on Chest X-Ray (CXR) Images. *SN computer science*, 4(2), 141. <https://doi.org/10.1007/s42979-022-01545-8>
- Cuadros, J., & Bresnick, G. (2009). EyePACS: an adaptable telemedicine system for diabetic retinopathy screening. *Journal of diabetes science and technology*, 3(3), 509–516. <https://doi.org/10.1177/193229680900300315>
- Das, S. CNN Architectures: LeNet, AlexNet, VGG, GoogLeNet, ResNet and more... Medium. <https://medium.com/analytics-vidhya/cnns-architectures-lenet-alexnet-vgg-googlenet-resnet-and-more-666091488df5> (2017, November 16)
- Das, T., Takkar, B., Sivaprasad, S., Thanksphon, T., Taylor, H., Wiedemann, P., Nemeth, J., Nayar, P. D., Rani, P. K., & Khandekar, R. (2021). Recently updated global diabetic retinopathy screening guidelines: commonalities, differences, and future possibilities. *Eye*, 35(10), 2685–2698. <https://doi.org/10.1038/s41433-021-01572-4>
- Decencière, E., Cazuguel, G., Zhang, X., Thibault, G., Klein, J.-C., Meyer, F., Marcotegui, B., Quéllec, G., Lamard, M., Danno, R., Elie, D., Massin, P., Viktor, Z., Erginay, A., Laÿ, B., & Chabouis, A. (2013). TeleOphta: Machine learning and image processing methods for teleophthalmology. *IRBM*, 34(2), 196–203. <https://doi.org/10.1016/j.irbm.2013.01.010>
- Decencière, E., Zhang, X., Cazuguel, G., Laÿ, B., Cochener, B., & Massin, P. (2014). Feedback on a publicly distributed image database: The MESSIDOR database. *Image Analysis & Stereology*, 33(3), 231–234

- Early Treatment Diabetic Retinopathy Study design and baseline patient characteristics. ETDRS report number 7. (1991). *Ophthalmology*, 98(5 Suppl), 741–756. [https://doi.org/10.1016/s0161-6420\(13\)38009-9](https://doi.org/10.1016/s0161-6420(13)38009-9)
- Flaxel, C. J., Adelman, R. A., Bailey, S. T., Fawzi, A., Lim, J. I., Vemulakonda, G. A., & Ying, G. S. (2020). Diabetic Retinopathy Preferred Practice Pattern®. *Ophthalmology*, 127(1), P66–P145. <https://doi.org/10.1016/j.ophtha.2019.09.025>
- Garner, A. (1993). Histopathology of diabetic retinopathy in man. *Eye (London, England)*, 7 (Pt 2), 250–253. <https://doi.org/10.1038/eye.1993.58>
- Ghasemi Falavarjani, K., & Nguyen, Q. D. (2013). Adverse events and complications associated with intravitreal injection of anti-VEGF agents: a review of literature. *Eye*, 27(7), 787–794. <https://doi.org/10.1038/eye.2013.107>
- Giancardo, L., Meriaudeau, F., Karnowski, T. P., Li, Y., Garg, S., Tobin, K. W., Jr, & Chaum, E. (2012). Exudate-based diabetic macular edema detection in fundus images using publicly available datasets. *Medical image analysis*, 16(1), 216–226. <https://doi.org/10.1016/j.media.2011.07.004>
- Goh, J. K. H., Cheung, C. Y., Sim, S. S., Tan, P. C., Tan, G. S. W., Wong, T. Y. (2016). Retinal imaging techniques for diabetic retinopathy screening. *Journal of Diabetes Science and Technology*.10 (2), 282–294. <https://doi.org/10.1177/1932296816629491>
- Gupta, V., & Arevalo, J. F. (2013). Surgical management of diabetic retinopathy. *Middle East African journal of ophthalmology*, 20(4), 283–292. <https://doi.org/10.4103/0974-9233.120003>
- Hajeb Mohammad Alipour, S., Rabbani, H., & Akhlaghi, M. R. (2012). Diabetic retinopathy grading by digital curvelet transform. *Computational and mathematical methods in medicine*, 2012, 761901. <https://doi.org/10.1155/2012/761901>
- Hendrick, A. M., Gibson, M. v., & Kulshreshtha, A. (2015). Diabetic Retinopathy. *Care - Clinics in Office Practice*. 42(3), 451–464). <https://doi.org/10.1016/j.pop.2015.05.005>
- Holm, S., Russell, G., Nourrit, V., & McLoughlin, N. (2017). DR HAGIS-a fundus image database for the automatic extraction of retinal surface vessels from diabetic patients. *Journal of medical imaging (Bellingham, Wash.)*, 4(1), 014503. <https://doi.org/10.1117/1.JMI.4.1.014503>
- Jin, K., Huang, X., Zhou, J., Li, Y., Yan, Y., Sun, Y., Zhang, Q., Wang, Y., & Ye, J. (2022). FIVES: A Fundus Image Dataset for Artificial Intelligence based Vessel Segmentation. *Scientific data*, 9(1), 475. <https://doi.org/10.1038/s41597-022-01564-3>

- Jung, E. E., Lin, M., Ryu, C., Moysidis, S. N., Burkemper, B., Murgai, R., Arbabi, A., & Ameri, H. (2021). Association of the pattern of retinal capillary non-perfusion and vascular leakage with retinal neovascularization in proliferative diabetic retinopathy. *Journal of current ophthalmology*, 33(1), 56–61. https://doi.org/10.4103/JOCO.JOCO_234_20
- Kauppi, T., Kalesnykiene, V., Kämäräinen, J., Lensu, L., Sorri, I., Raninen, A., Voutilainen, R., Uusitalo, H., Kälviäinen, H., & Pietilä, J. (2007). The DIARETDB1 Diabetic Retinopathy Database and Evaluation Protocol. *British Machine Vision Conference*.
- Klein, R., Lee, K. E., Gangnon, R. E., Klein, B. E. K. (2010). The 25-Year Incidence of Visual Impairment in Type 1 Diabetes Mellitus. The Wisconsin Epidemiologic Study of Diabetic Retinopathy. *Ophthalmology*, 117(1), 63–70. <https://doi.org/10.1016/j.ophtha.2009.06.051>
- Klein, R., Lee, K. E., Knudtson, M. D., Gangnon, R. E., Klein, B. E. K. (2009). Changes in Visual Impairment Prevalence by Period of Diagnosis of Diabetes. The Wisconsin Epidemiologic Study of Diabetic Retinopathy. *Ophthalmology*, 116(10), 1937–1942. <https://doi.org/10.1016/j.ophtha.2009.03.012>
- Li, T., Gao, Y., Wang, K., Guo, S., Liu, H. (2019). Diagnostic assessment of deep learning algorithms for diabetic retinopathy screening. *Information Sciences*, 501, 511-522. <https://doi.org/10.1016/j.ins.2019.06.011>
- Mehedi Shamrat, F. M. J., Shakil, R., Akter, B., Ahmed, M. Z., Ahmed, K., Bui, F. M., & Moni, M. A. (2024). An advanced deep neural network for fundus image analysis and enhancing diabetic retinopathy detection. *Healthcare Analytics*, 5, 100303. <https://doi.org/10.1016/j.health.2024.100303>
- Niemeijer, M., van Ginneken, B., Cree, M. J., Mizutani, A., Quellec, G., Sanchez, C. I., Zhang, B., Hornero, R., Lamard, M., Muramatsu, C., Wu, X., Cazuguel, G., You, J., Mayo, A., Li, Q., Hatanaka, Y., Cochener, B., Roux, C., Karray, F., Garcia, M., ... Abramoff, M. D. (2010). Retinopathy online challenge: automatic detection of microaneurysms in digital color fundus photographs. *IEEE transactions on medical imaging*, 29(1), 185–195. <https://doi.org/10.1109/TMI.2009.2033909>
- Oulhadj, M., Riffi, J., Khodriss, C., Mahraz, A. M., Bennis, A., Yahyaouy, A., Chraïbi, F., Abdellaoui, M., Andaloussi, I. B., & Tairi, H. (2023). Diabetic Retinopathy Prediction Based on Wavelet Decomposition and Modified Capsule Network. *Journal of digital imaging*, 36(4), 1739–1751. <https://doi.org/10.1007/s10278-023-00813-0>
- Pachade, S., Porwal, P., Thulkar, D., Kokare, M., Deshmukh, G., Sahasrabuddhe, V., Giancardo, L., Quellec, G., & Mériaudeau, F. (2021). Retinal Fundus

- Multi-Disease Image Dataset (RFMiD): A Dataset for Multi-Disease Detection Research. *Data*, 6(2), 14. <https://doi.org/10.3390/data6020014>
- Pires, R., Jelinek, H. F., Wainer, J., Valle, E., & Rocha, A. (2014). Advancing bag-of-visual-words representations for lesion classification in retinal images. *PloS one*, 9(6), e96814. <https://doi.org/10.1371/journal.pone.0096814>
- Porwal, P., Pachade, S., Kamble, R., Kokare, M., Deshmukh, G., Sahasrabudhe, V., & Meriaudeau, F. (2018). Indian diabetic retinopathy image dataset (IDRiD): A database for diabetic retinopathy screening research. *Data*, 3(3), 25. <https://doi.org/10.3390/data3030025>
- Prentašić, P., Lončarić, S., Vatavuk, Z., Benčić, G., Subašić, M., Petković, T., Dujmović, L., Malenica-Ravlić, M., Budimlija, N., & Tadić, R. (2013). Diabetic retinopathy image database(DRiDB): A new database for diabetic retinopathy screening programs research. 2013 8th International Symposium on Image and Signal Processing and Analysis (ISPA), 711–716. <https://doi.org/10.1109/ISPA.2013.6703830>
- Retinal Ophthalmology Database Repository. Retrieved from <http://www.rodrep.com/data-sets.html>
- Schindelin, J., Arganda-Carreras, I., Frise, E., Kaynig, V., Longair, M., Pietzsch, T., Preibisch, S., Rueden, C., Saalfeld, S., Schmid, B., Tinevez, J. Y., White, D. J., Hartenstein, V., Eliceiri, K., Tomancak, P., & Cardona, A. (2012). Fiji: an open-source platform for biological-image analysis. *Nature methods*, 9(7), 676–682. <https://doi.org/10.1038/nmeth.2019>
- Şevik, U., Köse, C., Berber, T., & Erdöl, H. (2014). Identification of suitable fundus images using automated quality assessment methods. *Journal of biomedical optics*, 19(4), 046006. <https://doi.org/10.1117/1.JBO.19.4.046006>
- Shakibania, H., Raoufi, S., Pourafkham, B., Khotanlou, H., & Mansoorizadeh, M. (2023). Dual Branch Deep Learning Network for Detection and Stage Grading of Diabetic Retinopathy. *arXiv preprint arXiv:2308.09945*. <https://doi.org/10.1016/j.bspc.2024.106168>
- Takahashi, H., Tampo, H., Arai, Y., Inoue, Y., & Kawashima, H. (2017). Applying artificial intelligence to disease staging: Deep learning for improved staging of diabetic retinopathy. *PloS one*, 12(6), e0179790. <https://doi.org/10.1371/journal.pone.0179790>
- Teng, T., Lefley, M., & Claremont, D. (2002). Progress towards automated diabetic ocular screening: a review of image analysis and intelligent systems for diabetic retinopathy. *Medical & biological engineering & computing*, 40(1), 2–13. <https://doi.org/10.1007/BF02347689>

- Teo, Z. L., Tham, Y. C., Yu, M., Chee, M. L., Rim, T. H., Cheung, N., Bikbov, M. M., Wang, Y. X., Tang, Y., Lu, Y., Wong, I. Y., Ting, D. S. W., Tan, G. S. W., Jonas, J. B., Sabanayagam, C., Wong, T. Y., & Cheng, C. Y. (2021). Global Prevalence of Diabetic Retinopathy and Projection of Burden through 2045: Systematic Review and Meta-analysis. *Ophthalmology*, 128(11), 1580–1591. <https://doi.org/10.1016/j.ophtha.2021.04.027>
- Wang, W., & Lo, A. C. Y. (2018). Diabetic retinopathy: Pathophysiology and treatments. *International journal of molecular sciences*, 19(6), 1816. <https://doi.org/10.3390/ijms19061816>
- Wilkinson, C. P., Ferris, F. L., 3rd, Klein, R. E., Lee, P. P., Agardh, C. D., Davis, M., Dills, D., Kampik, A., Pararajasegaram, R., Verdaguer, J. T., & Global Diabetic Retinopathy Project Group (2003). Proposed international clinical diabetic retinopathy and diabetic macular edema disease severity scales. *Ophthalmology*, 110(9), 1677–1682. [https://doi.org/10.1016/S0161-6420\(03\)00475-5](https://doi.org/10.1016/S0161-6420(03)00475-5)
- Wong, W. K., Juwono, F. H., & Apriono, C. (2023). Diabetic Retinopathy Detection and Grading: A Transfer Learning Approach Using Simultaneous Parameter Optimization and Feature-Weighted ECOC Ensemble. *IEEE Access*, 11, 83004-83016.
- Yang, Z., Tan, T. E., Shao, Y., Wong, T. Y., & Li, X. (2022). Classification of diabetic retinopathy: Past, present and future. *Frontiers in endocrinology*, 13, 1079217. <https://doi.org/10.3389/fendo.2022.1079217>
- Zhou, Y., Wang, B., Huang, L., Cui, S., & Shao, L. (2021). A Benchmark for Studying Diabetic Retinopathy: Segmentation, Grading, and Transferability. *IEEE transactions on medical imaging*, 40(3), 818–828. <https://doi.org/10.1109/TMI.2020.3037771>